

# Predictable apical microsurgery (Part II)

Author\_John Stropko, DDS

## \_c.e. credit

This article qualifies for C.E. credit. To take the C.E. quiz, log on to [www.dtstudyclub.com](http://www.dtstudyclub.com). The quiz will be available on June 15, 2012.

## \_The REB and REP

**\_The amount, or degree, of the root-end bevel (REB) is of utmost importance** and should be precisely planned in advance after considering the overall crown/root ratio, presence of posts or other obstacles, the root anatomy and the periodontal status of the tooth. According to previous research, 98 percent of canal system ramifications occur in the apical 3 mm.<sup>1</sup>

If the bevel is long (traditionally 25 degrees to 45 degrees) an excessive amount of root structure would have to be removed to include the apical 3 mm on the palatal, or lingual, part of the root's apical canal system (especially in roots with multi canals). If the bevel is closer to 0 degrees, the lingual 3 mm is easier to remove; more root structure can be conserved, improving the crown/root ratio. With a long bevel, there is also an increased risk of completely missing some important palatal, or lingual, anatomy, especially if the operator is in any measure trying to be conservative in order to preserve as much crown/root ratio as possible (Fig. 1).

The long bevel creates a spatial problem that is generally impossible for the operator to overcome while trying to visualize the true long axis of the canal system (Fig. 2). The longer the bevel, the greater the tendency is for the operator to leave more of the

palatal, or lingual, aspect of the root intact. Because it is difficult to visualize the long axis of the tooth, the resultant retroprep is not as likely to be within the long axis of the canal.

This concept is of utmost importance and is the primary reason that, on occasion, the retroprep unintentionally perforates to the lingual or palatal (Figs. 3a, 3b).

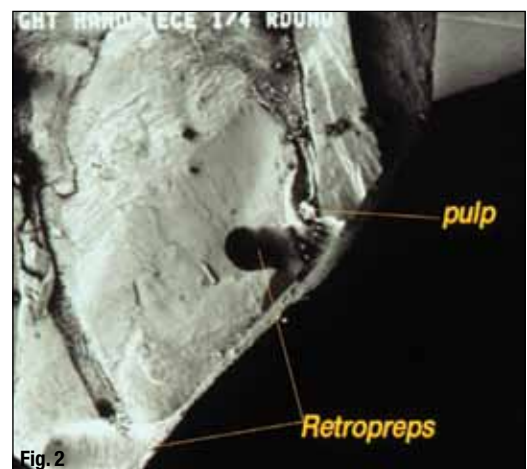
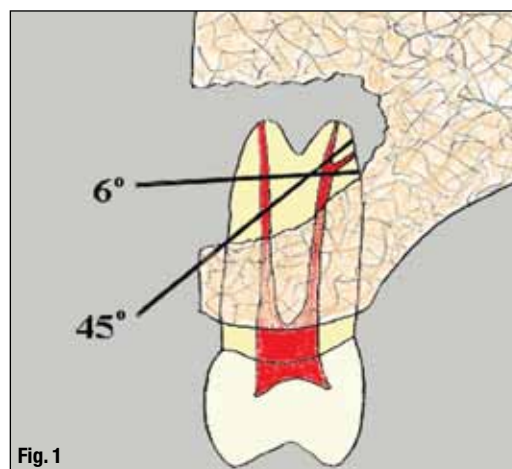
Another important consideration is, with a bevel as close to 0 degrees as possible, the cavo-surface marginal dimensions (bet you haven't heard that term in a while!) of the root end preparation will be considerably decreased. Therefore, the restoration will be easier to place and have less chance of leakage.

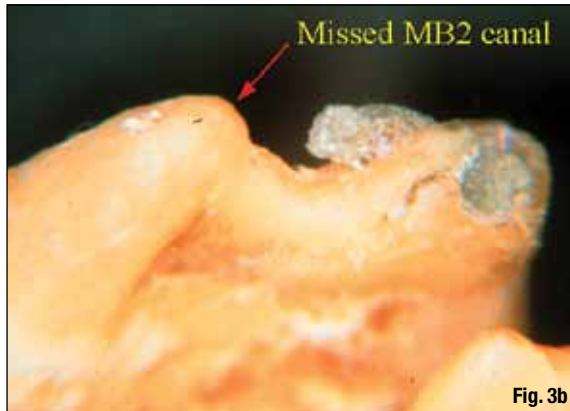
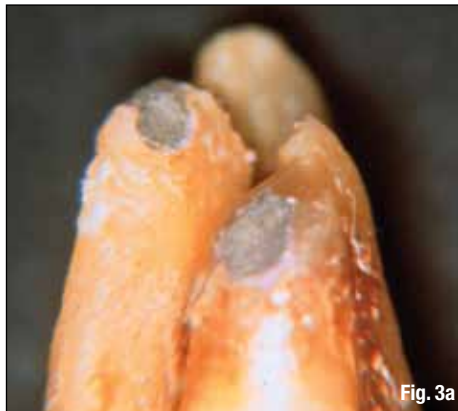The root anatomy is especially important when there are more than two canals in one root. This occurs most commonly in maxillary bicusps and in the mesial roots of nearly all molars. It has been shown that as many as 93 percent of the MB roots of the maxillary first molars have a second (MB2) canal.<sup>2</sup> However, the operator has to be constantly aware that multiple canals can occur in any root, no matter what tooth is being operated on. If there is an isthmus present, it can usually be seen with the OM if the root has been adequately beveled and stained with methylene blue.

The refinement of the bevel is best accomplished with a surgical length 1171 carbide-tapered fissure

**Fig. 1** Illustration of the effect that different bevel angles have on root length, including the missing of potential lingual anatomy. (Photos/ Provided by Dr. John Stropko, unless otherwise noted.)

**Fig. 2** Long bevel with round bur preps, demonstrating angulation and orientation problems, courtesy of Dr. Gary Carr.





**Figs. 3a, 3b** Inadequate and acute 45-degree bevel clearly shows how perforations can occur and canals can be missed. Fig. 3a is the surgeon's view from the buccal. Fig. 3b is what actually occurred but was completely missed by the operator.

bur (Brasseler) in a 45-degree handpiece (Sybron-Dental). These handpieces have no air exiting from the working end, which nearly eliminates the possibility of an air emphysema, or air embolism, beneath the flap.

A standard high-speed handpiece should never be used for the above reason. On occasion, the refinement of the bevel can cause additional bleeding due to some enlargement of the crypt. The operator should address any newly created crypt management problem before proceeding any further. Remember that it is of utmost importance to fully complete one step before proceeding to another!

After the REB is refined and crypt management is completely under control, the apical surface is rinsed and dried with a Stropko Irrigator ([www.stropko.com](http://www.stropko.com)). The clean and dried surface is then stained with methylene blue. It is important to allow the methylene blue to remain on the tooth for just a short period of time before gently rinsing and drying again to enable inspection of the stained surface.

Normally, a fresh, white piece of Telfa is reinserted for better lighting. If there are any fractures, presence of isthmus tissue or accessories present, the staining will greatly enhance the operator's ability to visualize them. Also, the methylene blue will stain the periodontal ligament and enable the operator to be sure the apex has been completely resected (Fig. 4). If there is an accessory canal present, the easiest answer is usually to bevel past it and restrain. Or, on occasion, the accessory can be "troughed out," leaving the bevel as is.

When two canals are present in the same root, it is necessary to prepare for an isthmus between the two canals even if the staining didn't reveal one. It has been shown that in the mesiobuccal roots of the maxillary first molars with two canals, the 4 mm section displayed a partial or complete isthmus 100 percent of the time.<sup>3</sup> This combined with the finding in the same root in maxillary molars, that two canals present clinically at least 93 percent of the time in the mesiobuccal root of the maxillary first molar,

lends importance to always preparing isthmus area of the REB.<sup>2</sup>

Although staining doesn't always reveal the presence of an isthmus, it may lie just below the surface, only to be exposed during the remodeling process of the surface of the beveled root that normally takes place during the healing process (Fig. 5). The rule is to always prepare an isthmus when there are two canals in one root.

The preparation of the root-end preparation (REP) is best accomplished using ultrasonics. There are many different ultrasonic units available. For the most part, they are all dependable and have a good service record. There are multitudes of ultrasonic tips to choose from. The newer diamond coated and vented tips (ProUltra Tips from DENTSPLY Tulsa Dental or KIS Tips from Obtura/Spartan) are much more efficient and especially good at removing gutta-percha.

The most important consideration is not the brand of the ultrasonic unit or type of tip but how the instrument is used. The tendency for the new operator is to use the ultrasonic in the same manner (pressure-wise) as the handpiece. The secret is to start at a low power setting and use an extremely light touch! The lighter the touch, the more efficient the action of the tip will be.

The correct amount of coolant is also important. If too much spray is used, visibility and cutting efficiency are both decreased. If too little spray is used, the necessary amount of cooling will not be available and overheating and/or micro cracks can be the result.

The occasional left and right, variously angled tips are necessary on occasion, but in most cases, the anterior type tips will suffice. If the canal is large and/or filled with gutta-percha, a larger, coated tip can be used most efficiently. The key is to: 1) slow down; 2) be gentle; 3) use a light, brushing movement; and 4) carefully regulate the power setting of the ultrasonic unit. The power setting will vary greatly depending on the tip being used and nature of the preparation task at hand.

**Fig. 4**\_Staining allows the operator to be sure of complete root resection, and to see if there is an isthmus, accessory or fracture present.

**Fig. 5**\_An illustration of an isthmus, lying just below the surface that would not be evident, even after staining with methylene blue

**Fig. 6a**\_The series of 'dots' permit easy and accurate preparation of an isthmus in a root end that is very thin.

**Fig. 6b**\_While still dry, the 'dots' are connected until there is a shallow, but definite 'tracking groove.'

**Fig. 7**\_A modified and pre-bent needle is used to clean and dry the REP for good vision.

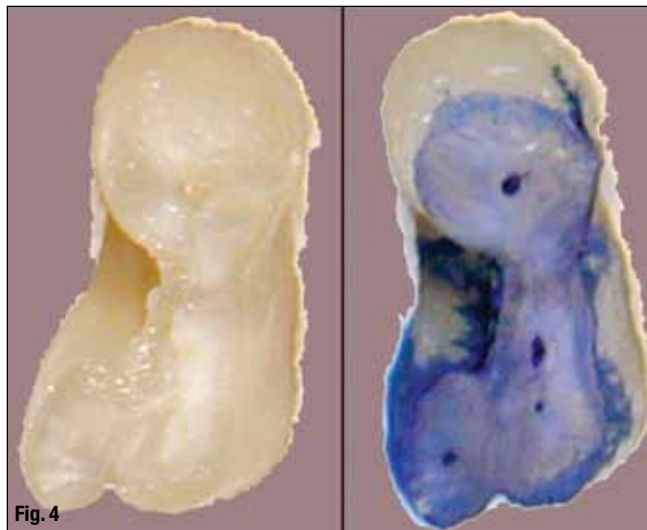


Fig. 4

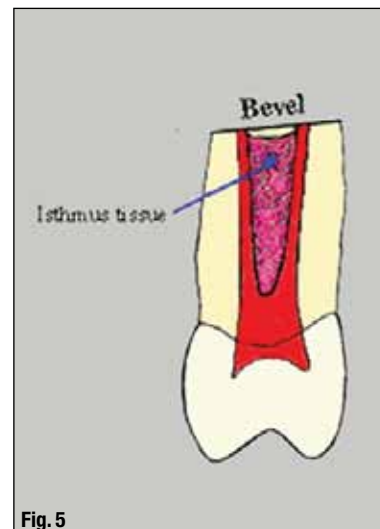


Fig. 5

For the preparation of an isthmus, an uncoated, fine-pointed tip (CT-1 by SybronEndo) is inserted into the ultrasonic and used to create a precise series of multiple "dots" on the stained or "imaginary" line between the two canals. For the DOT Technique, the ultrasonic unit is set at a low power setting but inactivated, water spray is turned off, a CT-1 tip is placed exactly where desired and the rheostat is "tapped" for just an instant. The process is repeated again, and

again, as many times as necessary, until there are a series of "dots" (Fig. 6a). Then, while the water spray is still off, the dots are gently connected to create the initial, shallow but precise "tracking groove" (Fig. 6b).

The DOT Technique is of great value, especially when there is concavity present and the width of the beveled root is very thin mesial to distal. The resultant groove serves as a definite guide for the completion of the isthmus portion of the REP. Then with the water spray turned back on and the power increased slightly, a pointed, coated tip can be used more aggressively to deepen the tracking groove. In this manner, accuracy is completely controlled and there is no chance of "slipping off" while preparing the isthmus in a very thin root. On occasion, if the walls of the prep become too thin, further beveling may be necessary.

Occasionally throughout the REP process, it is important to use the Stropko Irrigator to rinse and dry the REP to be sure it is kept within the long axis of the canals and all debris is being removed as planned. Various sizes of micro-mirrors, or an endoscope, are used to periodically inspect the preparation and confirm accuracy.

A pre-cut and pre-bent 25 gauge endodontic irrigating needle (Monoject) works well for this purpose. The notched end is removed by rapidly bending the end one-third back-and-forth with a Howe Pliers. The needle inserted into the Stropko Irrigator is then bent similar to the ultrasonic tip to be used for the REP (Fig. 7). Always keep in mind that cleanliness and dryness are essential for good visibility when using the OM.

Of particular interest is the buccal aspect of the internal wall of the REP. Dr. Rubinstein was the first to point out that often this area is not debrided due to the angulation of the ultrasonic tip within the canal system during the REP. If there is some gutta-percha "streaming up" the side of the wall, and

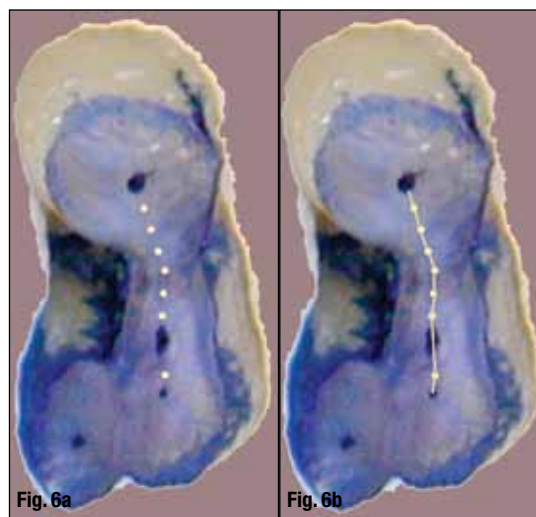


Fig. 6a

Fig. 6b




Fig. 7



the preparation is finished, the best thing is to take a small plugger and fold the gutta-percha coronally so the wall is clean once more. It is usually futile to try to "chase after" the gutta-percha with an ultrasonic tip.

The ideal REP should: 1) be within the long axis of the canal system; 2) have parallel walls; 3) be at least 3 mm in depth (including the isthmus portion of the preparation); 4) adequately extended to include any buccal/lingual variations of the canal system; 5) be clean (free of a smear layer) and 6) be dry and ready to accept any type root-end filling material.

After completion of the REP, it should be rinsed and dried once more with the Stropko Irrigator. The REP is re-inspected, using micro-mirrors and the varying powers of the OM and/or endoscope, to be sure it is clean and within the long axis of the canal system. At this time, the REP is etched with blue 35 percent phosphoric acid gel (Ultra-Etch by Ultradent) to remove the smear layer. After 15 to 20 seconds, the REP is thoroughly rinsed and dried with the Stropko Irrigator and re-examined with the OM.

If all is as desired, a 15-second rinse with 2 percent chlorhexidine will help eliminate any residual organisms present. One more gentle rinsing and drying with the Stropko Irrigator and the REP is ready for the root-end fill (REF).

### REF materials, techniques

The necessary steps and procedures have been presented, enabling the operator to atraumatically and predictably allow the root-end preparation (REP) to be sealed using any accepted root-end fill (REF) material.

The surgical crypt should be clean and dry so vision is clear and unobstructed. Remember, the steps must be followed completely in order to achieve as predictable a result as humanly possible. If, for some

reason, crypt management is not complete, or the REP is not clean and finished, it is required to "go back" and repeat a step, or two, to achieve the desired result. The importance of having total control at this point in the apical microsurgical procedure cannot be over-emphasized.

The operator is now at a stage in the microsurgical procedure where the tissues have been atraumatically retracted, the crypt is well-managed and the acid etched; rinsed and dried REP is ready to fill. Removing the smear layer barrier, exposing the organic component (collagen fibrils) of the resected cementum and dentin, has been shown to enhance cementogenesis and is one of the keys to dentoalveolar healing.<sup>7</sup>

There are several materials that are currently available as a retrofill: amalgam, IRM, Super EBA "SEBA" (Bosworth, USA), bonded composites Optibond (SybronDental, United States), glass ionomers, such as Geristore (Den-Mat, United States) and more recently, Mineral Trioxide Aggregate "MTA" (DENTSPLY Tulsa).

The number of publications in literature about research on the above materials is extensive, so only a few of them will be mentioned due to space. The author doesn't want to recommend or disapprove of any retrofill material (except amalgam), but will generalize and relate his and others' experience with them and opinions about their applications.

Amalgam and IRM were used for many years as the only commonly available retrofill materials. However, in almost every "leakage" study published during the past few years, amalgam has proved to be the worst offender, exhibiting the most leakage.<sup>5,6</sup> This fact, accompanied by the general controversy about mercury in amalgam, strongly suggests that there is no valid reason to continue its use as a retrofill material. The only real advantage to amalgam is the

**Fig. 8a** Amalgam is the most radiopaque REF material, but its use is highly controversial.

**Fig. 8b** SEBA has a radiopacity similar to that of gutta-percha.

**Fig. 8c** The MTA has a radiopacity just slightly better than gutta-percha.

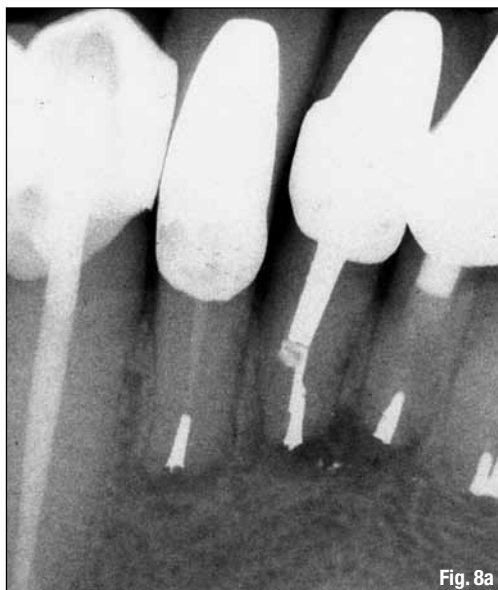


Fig. 8a

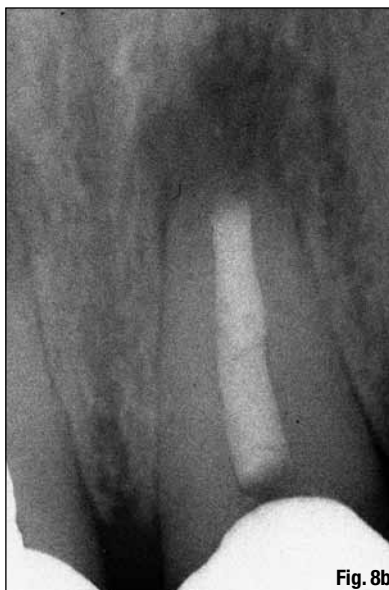


Fig. 8b

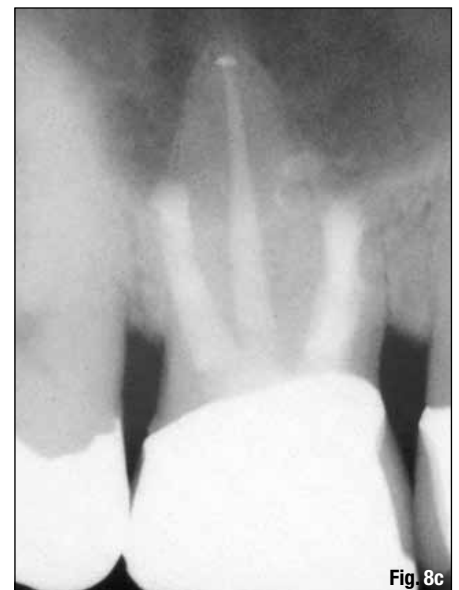


Fig. 8c

**Figs. 9a, 9b**\_Lee MTA Pellet Forming Block.

**Figs. 9c-9e**\_Using the Lee MTA Pellet Forming Block system, it takes fewer 'passes' with the instrument to complete the fill of the REP with MTA.



**Fig. 9a**



**Fig. 9b**

favorable radiopacity (Fig 8a). In fact, of all REF materials commonly in use today, none of them compare to the radiopacity of amalgam.

Since the advent of the anatomically correct, ultrasonic REP, one of the most popular and still-used REF material is Super EBA (SEBA). A recent follow-up study demonstrated a success rate of 91.5 percent using SEBA.<sup>7</sup> The author used SEBA routinely in the early 1990s with full confidence of its sealing capabilities.

To some, the major drawback of SEBA is its technique sensitivity. The surgical assistant had to mix it until it was thick enough to roll into a thin tapered point with a dough-like consistency. For even a well-trained assistant, this was often the most stressful part of the microsurgical procedure. The "dough-like" tapered end of the thin SEBA "roll" was then segmented with an instrument, such as a small Hollenbeck Carver.

The small cone-shaped endpiece was then inserted into the retroprep and gently compacted coronally with the appropriate plugger. Two to five of these small segments were usually necessary to slightly overfill the retroprep.

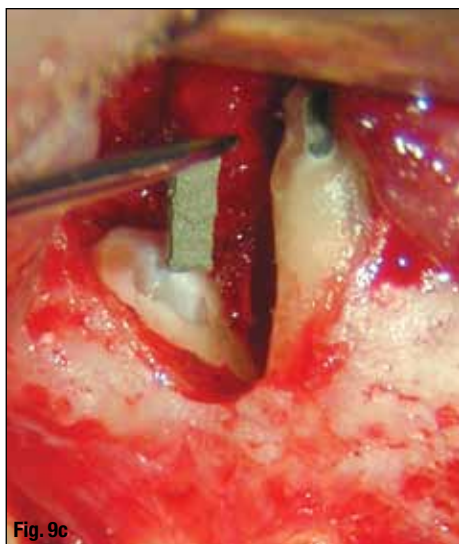
Another problem experienced by many was that SEBA was unpredictable as to its setting time —

sometimes setting too quickly and, at other times, taking much too long for the tired surgeon.

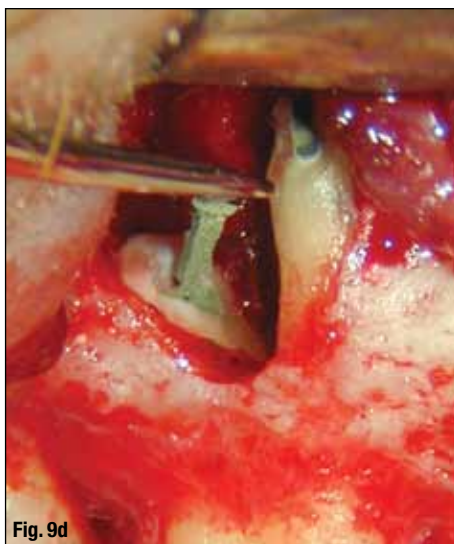
At any rate, after the REF is complete, an instrument, and/or bur, is used to smooth the resected surface, producing the final finish. A mild etchant is then used to remove the "smear layer" produced during the final finishing process. SEBA has a radiopacity comparable to that of gutta-percha, so it was necessary to educate the new referring doctor that a retrofill had indeed been performed (Fig. 8b). However, in some recent studies, SEBA has been shown to have a better sealing ability that IRM, but not as well as MTA.<sup>5,6</sup>

Bonding, using composite retrofill materials, is now completely possible due to having total control over the apical environment utilizing good crypt management procedures. Many different materials are available for use as a REF. Optibond (SybronDental) and Geristore (Den-Mat) are popular because of their ease of use. They both have good flowability, dual-cure properties and the ability to be bonded to dentine. Geristore is supported by research demonstrating biocompatibility to the surrounding tissues.<sup>8</sup>

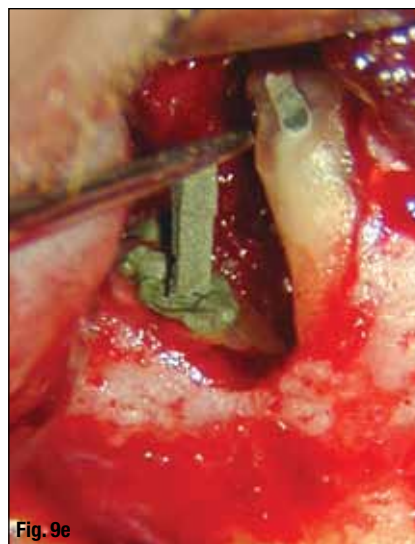
The usual etching, conditioning of the dentin, insertion of the selected material, and curing by chemical or light is accomplished in a routine manner



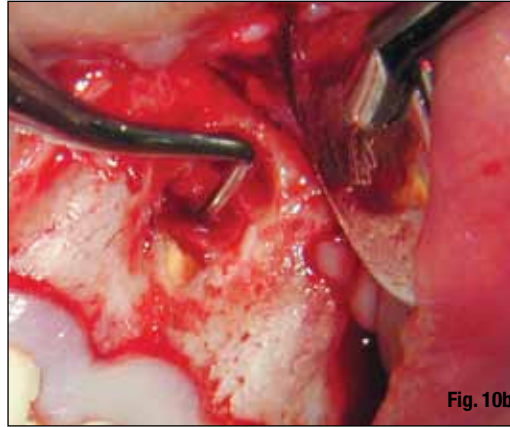
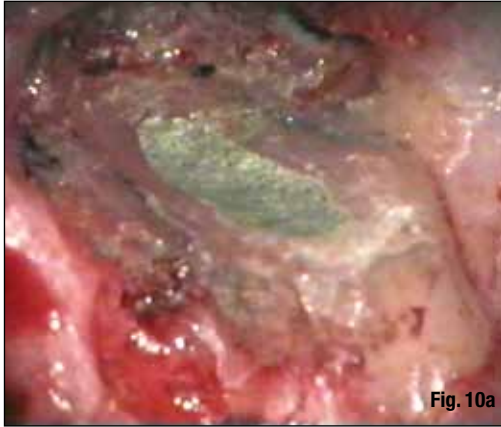**Fig. 9c**



**Fig. 9d**



**Fig. 9e**



**Fig. 10a**\_MTA should be carved flush with the REB.

**Fig. 10b**\_Blood supply re-established to cover MTA.

when bonding into the retroprep. (Note: Because the light source for the OM is so intense, it is mandatory to obtain an orange filter to use while placing the composite to prevent a premature set.) For most microscopes, an orange filter is available that easily and inexpensively replaces the "blood filter." After the composite is completely cured, the material is finished with a high-speed finishing bur and the resected root end is etched with a 35 percent blue gel etchant (Ultradent, United States) for about 12 seconds to remove the "smear layer" and to demineralize the surface.

Several studies showed no leakage with bonding techniques and many operators use it as their technique of choice.

However, there is some controversy as to whether the resected surface of the root should also be coated with a thin layer of the bonding material. A "cap" of material (usually Optibond) was placed with the intention of sealing the exposed tubules on the resected surface.

The operators who cover the resected surface believe it necessary to ensure a good seal and the predictability would be better. On the other hand, there are also operators who do not believe the exposed tubules are a factor concerning the predictability of the healing process. They reason that nothing would heal as well, or be more biocompatible, than the exposed dentin of the apically resected surface.

The author did not cover the exposed apical surface and is convinced the jury is still out on this issue!

More recently, another material has become very popular and is widely used by many. Mineral Trioxide Aggregate (MTA) has attracted many converts. There is so much research that has been done, and so many publications presented, that just one reference would be futile.

The evidence extolling the virtues of MTA, regarding its sealing capabilities and its biocompatibility with the surrounding tissues, is overwhelming. The author has talked to many respected endodontists, and most are now using MTA as their routine retrofill

material. MTA is chemically similar to calcium sulfate, forgiving to work with, and has a radiopacity slightly better than gutta-percha (Fig. 8c).

The main advantage of MTA is its ease of use, much like handling "Portland Cement." One of the secrets to using MTA is to keep it dry enough so it doesn't flow too readily (like wet sand), but yet is moist enough to permit manipulation and maintain a workable consistency.

The desired "thickness" is easily accomplished by using dry cotton pellets, or the MTA mix can be gently dried with a dedicated, air-only Stropko Irrigator ([www.stropko.com](http://www.stropko.com)). If the MTA is too dry and needs moisture added, that, too, is easily done with a cotton pellet saturated with sterile water. Properly mixed MTA can be extruded in pellets of various sizes (depending on the size of the carrier used) using a Dovgan Carrier (Quality Aspirators) and condensed with an appropriate plugger.

More recently, a simple method for delivery of the MTA into the REP was introduced (Fig. 9a). The Lee MTA Pellet Forming Block has several differently sized grooves to create the desired aliquot of MTA. The MTA adheres to the instrument, allowing for easy and efficient placement into the REP (Figs 9c-9e).

For a denser and stronger consistency, the assistant can touch the non-working end of the plugger, or explorer, with an ultrasonic tip during the condensation process. The flow is increased and a much denser fill is achieved. As a result, "ultrasonic densification" also increases the radiodensity of the MTA's appearance in the post-op radiograph, but it is still similar to gutta-percha (Fig. 8c).

MTA has approximately an hour of working time, which is more than adequate for apical microsurgery and takes much "time pressure" out of the surgical procedure. Finishing the MTA is simply a matter of carving away the excess material to the level of the resected root end (Fig. 10a). The moisture necessary for the final set is derived from the blood, which fills the crypt after surgery. The MTA is very hydrophilic and depends on moisture for the final set, so it is im-



perative that there is enough bleeding re-established after crypt management to ensure the crypt is filled. If any material, such as ferric sulfate, has been used for crypt management, it must be judiciously removed to restore blood supply to the crypt.

This can be considered the final step in "crypt management" and is especially important when MTA is used for the REF. If the size of the lesion indicates the use of guided bone regeneration, good blood supply is indicated anyway, so allow the blood to cover the MTA before placing the GBR material of choice. In a large lesion, it is sometimes difficult, even after curettage, to restore bleeding into the crypt (perhaps the crypt management was a little too effective), and it may be necessary to use a small round bur in the surgical handpiece to make several small holes in the surface of the crypt to aid in the re-establishment of the desired flow of blood.

Based on current studies, the operator can choose any one of the above mentioned REF materials and be comfortable that, if the proper protocol is followed, the apical seal will be predictable and healing uneventful.

### Sutures, suturing techniques

All steps have been meticulously followed, the REF has been placed, the crypt has refilled nicely, the final radiograph has been approved, and it is time to suture the flap into position.

Sadly, most operators now push the microscope aside and suture without it. To do this robs the operators of an opportunity to demonstrate to themselves and their patients the amazing capabilities of the OM. The doctors must make a commitment to master the suturing technique using the OM.

It will never be accomplished with the OM pushed aside at this critical step in the apical microsurgical procedure. The following will be based largely on the author's own experiences during nearly 20 years of doing, teaching and writing about apical microsurgery.

Dr. John Harrison has published some of the most clearly written and comprehensive work on wound healing associated with periapical surgery.

There are five publications that are a "must read" for the endodontic surgeon. These publications can be found in the *Journal of Endodontics*: 1991, Vol. 17, pp. 401-408, 425-435, 544-552; 1992, Vol. 18, pp. 76-81; and 1993, Vol. 19, pp. 339-347.

After reading these articles, the microsurgical protocol developed by Drs. Gary Carr, Richard Rubinstein and others becomes clearer and is more easily understood. The word "atraumatic" is an important factor to achieve predictable wound healing.

When the surgical site is ready for closure, the flap should be gently massaged to close approximation with the attached tissue. But, keep in mind, the flap has probably lost dimension, or "shrunk" slightly, due to the mere act of retraction over a period of time and has endured a slight decrease of blood flow to it. Fortunately, this is usually not a problem. If the initial incision was planned with this final step in mind, the tissues should re-approximate with minimal manipulation. Now is when the operator will appreciate nice "scalloping" and a sharp scalpel when making the incision in the beginning of the surgery (Fig. 11).

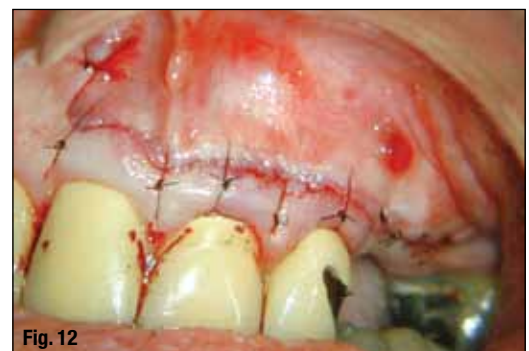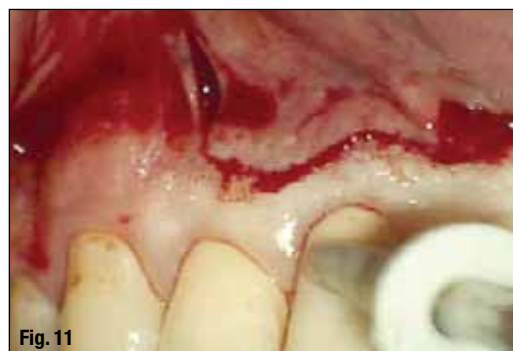Remember the old saying, "Hindsight is always 20/20"? The smooth side of a small #2 mouth mirror can be used to hold the tissue in position while the second surgical assistant (on the same side of the chair as the doctor) hands the doctor the needle holder with the needle positioned properly in the beaks so the sutures can be easily and accurately placed.

All suturing is accomplished using 6-0 black monofilament nylon (Supramid, S. Jackson). Some microsurgeons are using 8-0 and, even 10-0 sutures; but the 6-0 is easy to use, doesn't tear through the tissue as readily and the results are no different than with the more technique-demanding, thinner sutures. Keep in mind, the sutures will be removed in 24 hours so it is really a moot point as to whether the suture is 6-0, 8-0 or 10-0.

The results achieved with 6-0 suture seem to be well suited to apical microsurgery. The black silk suture, traditionally used in surgery, is a detriment to the rapid healing we are trying to achieve. Not only does bacterial plaque more readily accumulate on it than monofilament but, also, the braiding

**Fig. 11** If the incision is planned well, re-approximation of the flap is uneventful.

**Fig. 12** Sutures immediately post-operation.



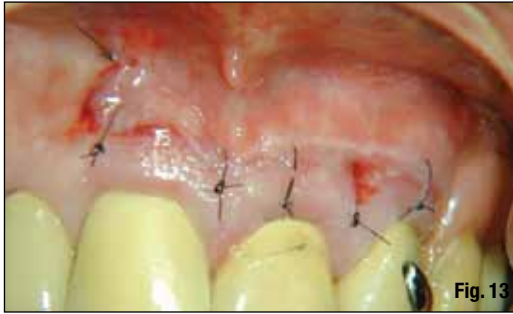

Fig. 13

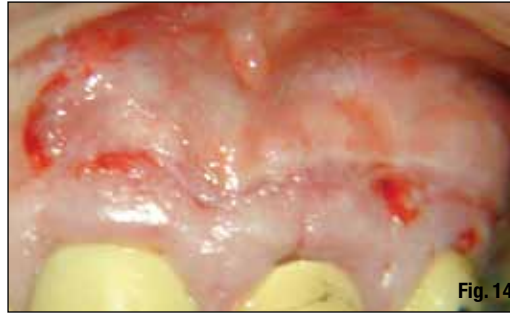

Fig. 14

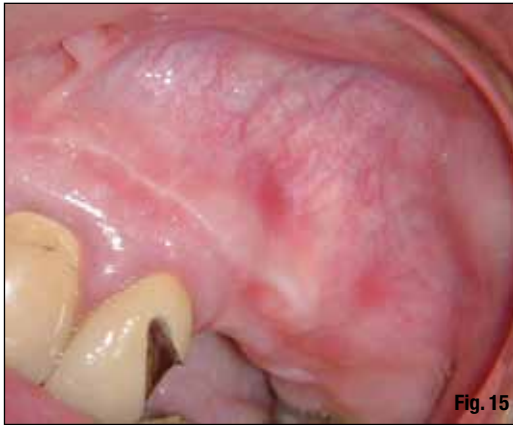


Fig. 15

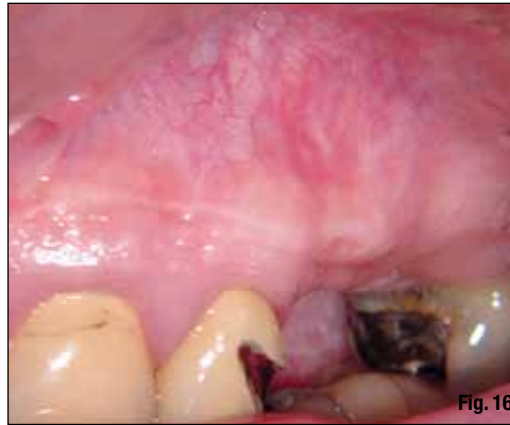

Fig. 16

**Fig. 13\_** Twenty-four hours post-operation; before sutures are removed.

**Fig. 14\_** Appearance of the tissue immediately after the 24-hour suture removal.

**Fig. 15\_** Two weeks post-operative, the healing is proceeding as expected.

**Fig. 16\_** At six months post-operative, nothing is seen except the scar from a previous apical surgery done 10 years ago.

acts as a wick for the migration of bacteria into the wound. This can result in an increased inflammatory response and compromised healing.

The type of needle used depends on the type of flap to be sutured. For the Oshenbein-Leubke Flap, a taper point needle (TPN), 3/8 circle (Supramid, S. Jackson, code MEA-60B) is used.

The TPN is far superior to the reverse cutting type needle (RCN) because there isn't the tendency to cut, or tear, the flap edges. Also, the TPN require less effort to exit at a point in the attached tissue where the operator intends, not where the needle wants to exit.

In other words, it is easier to guide a TPN to the desired point of exit in the attached tissue than it is an RCN. They just seem to cooperate more when suturing this type of flap! One of the nicest things about using this flap design is the ability to easily see the healing taking place (Figs. 12–16).

For the Sulcular Flap, a reverse cutting needle (RCN), 3/8 circle (Supramid, S. Jackson, code MPR-60B) is used. This needle is used because the larger size facilitates passing it through the contacts when doing a sling suture. The sling, or mattress type, suture is routinely used to save time on closure, rather than doing individual buccal to lingual sutures. On many occasions, the TPN (see above paragraph) is also used to suture the attached gingival area of the flap at the coronal aspect of the releasing incision.

A technique for suturing using the SOM: While the scope assistant holds the retractor in place, the second assistant uses a small Castro-Viejo type needle holder. The beaks of the holder must grasp the needle

approximately 3/4 of the distance from the pointed end to where the suture is attached to the needle. Special attention, by the second assistant, must be taken to keep the beaks of the holder away from either end of the needle, as these are the areas of the needle's greatest weakness and can be inadvertently bent or broken (Fig. 17).

Care is taken so the needle is firmly grasped perpendicular to the beaks of the holder. This allows the operator more definite control and a better "feel" of the needle during the suturing process.

The second assistant now passes the needle holder into the doctor's normal working hand (Hand A). The doctor then begins the suturing process by inserting the needle through both sides of the incision. When the needle is completely through both sides of the incision, the needle is then grasped between the thumb and index finger of the opposite hand (Hand B).

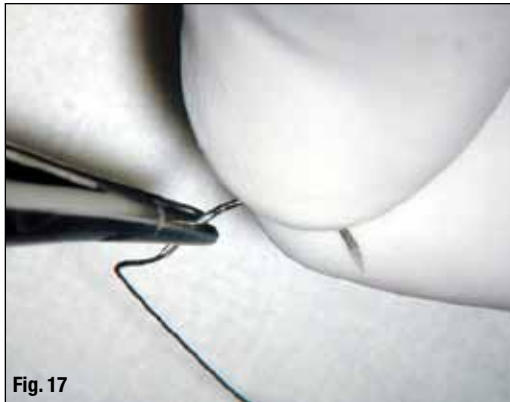
While the doctor is doing this, the second assistant is holding the end of the suture so it won't inadvertently be pulled through the tissues. The doctor proceeds to make the three loose "loops" around the beaks of the needle holder to start the first knot.

While the doctor is making these initial "loops," the second surgical assistant is placing the end of the suture into the doctor's visual field of the microscope, so the end of the suture can be easily grasped in the beaks of the needle holder by the doctor.

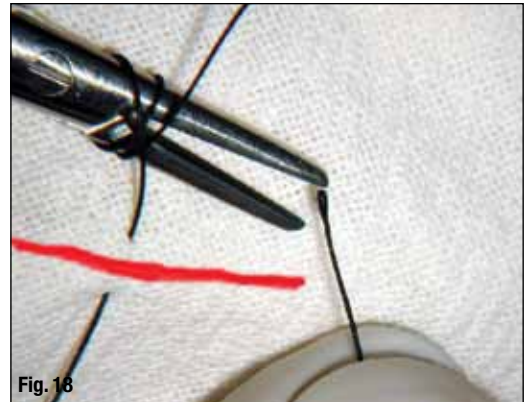
The second assistant can be sure the end of the suture is within the doctor's field of vision by looking into a monitor that has been placed so it is easily seen (Fig. 18).



**Fig. 17\_** The needle must be placed into the beaks of the needle holder correctly.



**Fig. 18\_** The second assistant presents the end of the suture so the doctor can control it.



The "loops" around the beaks of the needle holder create enough friction so there is a controllable tension between the doctor's Hand B and the beaks of the needle holder in Hand A. Care must always be taken that the tension is only between Hand B and the needle holder in Hand A, so no undesirable tension is exerted on the tissue during the suturing process.

The purpose of maintaining some tension is to give the doctor a positive tactile sense while taking up the excess suture material in Hand B. As the suture is drawn through the tissue by Hand B, Hand A is lowered to prevent exerting too much tension on the tissue.

The tension on the suture is regulated by the looseness, or tightness, of the "loops" which control the amount of friction for the suture to overcome as it is gathered. Hand B continues gathering as Hand A yields the suture with a "descending" motion while still maintaining the desired tension, and the beaks of the holder have the end of the suture firmly secured.

When the end of the suture is at the desired length relative to the incision, the "loops" are allowed to slip off the beaks for the initial knot. Then, using the same basic rhythm of movements, the "securing" and "locking" knots are placed. It is an alternating rhythm of movement that is difficult to describe in writing, but is actually very easy for the beginning microsurgeon to learn.

The doctor now allows the second surgical assistant to take the needle holder from Hand A and simultaneously be handed the micro-scissors so the suture can be cut close to the knot.

After the second assistant takes the scissors and the suture, the doctor is handed a micro-forceps to gently move the knot between the point of insertion and the incision, helping to prevent plaque buildup over the incision itself (Fig. 19).

Note: When moving the knot with the micro-forceps, it is important that the knot be "pushed" to place, not "pulled" to place. This ensures the suture's original tension and integrity is maintained.

One of the most common mistakes made when

suturing is to make the suture too tight. It is better to make the suture a little too loose than to make it too tight. When the suture is too tight, it causes ischemia and thus compromises rapid healing. When making a sling suture in a sulcular flap, it is easy to be too aggressive when tying the knot, causing the rest of the suture to get too tight. The doctor should always recheck the tension over the entire length of the suture before completing the securing knots.

The releasing incision is usually an integral part of every flap and is considered differently from the rest of the incision. Normally, the releasing incision is not sutured, but if it is, the suture should be looser than the other sutures. It has been shown that epithelial creep, or streaming, occurs rapidly, or at a rate of about 1 mm per side per 24 hours.

In other words, a wound whose edges were separated 2 mm would be expected to come together within a 24-hour period. In hundreds of surgeries during the past 12 years, there were only a few cases where the releasing incision wasn't completely closed.

Of those few that didn't close within 24 hours, they all closed within 48 hours. To repeat: If the operator prefers to suture the releasing incision, it must be sutured loosely (Fig. 20). Another consideration is to be sure to suture "like tissues to like tissues." Never suture attached gingival tissue to unattached gingival tissue. If one side of the suture "tears out," it will be the attached gingival side.

When using the OM to suture, the incision can be closed accurately with extremely good approximation. It is because of well-planned and nicely scalloped incisions; atraumatic flap elevation procedures; and the very close repositioning of the flap with thin, hair-like sutures (6-0) that we can plan on routinely removing sutures in 24 hours (see Figs. 16 and 17).

The sutures have completed their task after 24 hours, and in fact, have now become foreign bodies that can cause irritation, excessive inflammation, be a source of infection and, ultimately, result in a retardation of the healing process.<sup>14</sup>

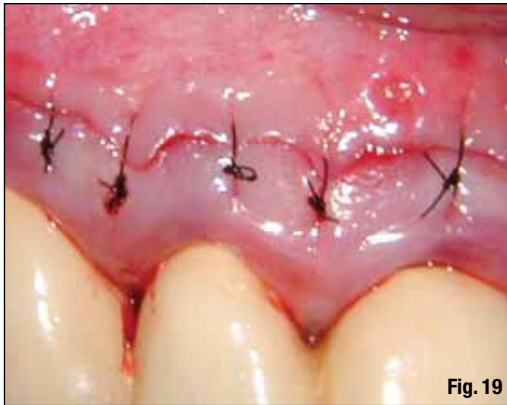


Fig. 19

For those who doubt the 24-hour Suture Removal Theory, an easy exercise is this:

- 1) At the next surgery, be sure to place at least five sutures.
- 2) After 24 hours, have the patient come in and remove the worst-looking suture, the one you think isn't healing as well as the others.
- 3) Then, the next day, remove the next worst-looking suture.
- 4) The next day, do the same, and so on. At the end of the fifth day, the worst-looking suture will be the one remaining! If that doesn't convince you, nothing will.

Post-operatively, the usual result is little, or no, pain or swelling. The post-operative instructions are ice packs 15 minutes on and then 15 minutes off for the first six hours only, gentle rinsing with Peridex for the next 24 hours, and have sutures removed the next day. Experience has demonstrated that prescribing Ibuprofen 600mg every six hours, along with on to two tabs of Tylenol OTC (taken between the doses of Ibuprofen), has a very effective anti-inflammatory effect.

It is the exception, rather than the rule, that a patient requires a stronger medication for post operative pain. Antibiotics are not usually prescribed.

If everything is within normal limits, the patient is instructed to begin gentle cleaning of the area on the third day post-op, using a wash cloth over his or her index finger, and to begin gentle brushing, with a soft brush, on day five. The patient is scheduled for a follow-up visit two weeks after surgery.

At the two-week visit, normally the incision is barely visible, and on most occasions, can hardly be detected.

A word of caution: Not all patients respond to treatment as well as others. Don't be in a hurry to treat a problem that may not exist. On a few occasions, patients may be slower than normal in response to treatment, sometimes taking several weeks to heal as well as other patients have or do in just days.

If there is any doubt, place the patient on antibiotics and an anti-inflammatory for a week as a precaution, but what is really desired is more time for delayed healing to occur.

The apical microsurgical technique described in

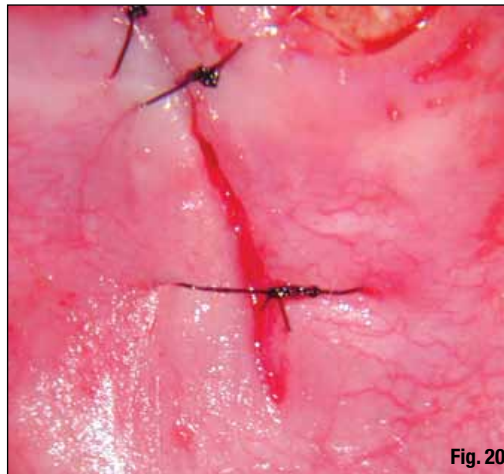


Fig. 20

**Fig. 19\_** The suture knot is 'pushed' into the proper position, not 'pulled.'

**Fig. 20\_** If the vertical releasing incision is sutured, it must be kept very loose.

the previous six parts has become the standard of care in endodontic treatment and raises endodontic apical surgery to a new and exciting level.

For the first time, apical surgery can be performed with predictable results. But these results can only be achieved if the proper protocol is followed meticulously.

The steps must be followed without compromise. Much more could be written, but hopefully enough of an overview has been given to stimulate just one more doctor to begin using the OM. It is the finest tool our profession has ever been given.

Apical microsurgery can be an enjoyable part of the daily regimen, for both the doctor and the newly involved dental team.\_

*Editorial note: Part I of this article appeared in roots, the international magazine of endodontics, Vol. 1, No. 1, 2011. A complete list of references is available from the publisher.*

#### \_about the author

#### roots

John J. Stropko received his DDS from Indiana University in 1964, and he practiced restorative dentistry for 24 years. In 1989, he received a certificate for endodontics from Boston University and recently retired from the private practice of endodontics in Scottsdale, Ariz. Stropko is an internationally recognized authority on micro-endodontics. He is the inventor of the Stropko Irrigator, has published in several journals and textbooks and is an internationally known speaker. He is the co-founder of Clinical Endodontic Seminars and was an instructor of microsurgery for the endodontic courses presented at the Scottsdale Center for Dentistry. Stropko and his wife, Barbara, currently reside in Prescott, Ariz. You may contact him at [docstropko@gmail.com](mailto:docstropko@gmail.com).

